

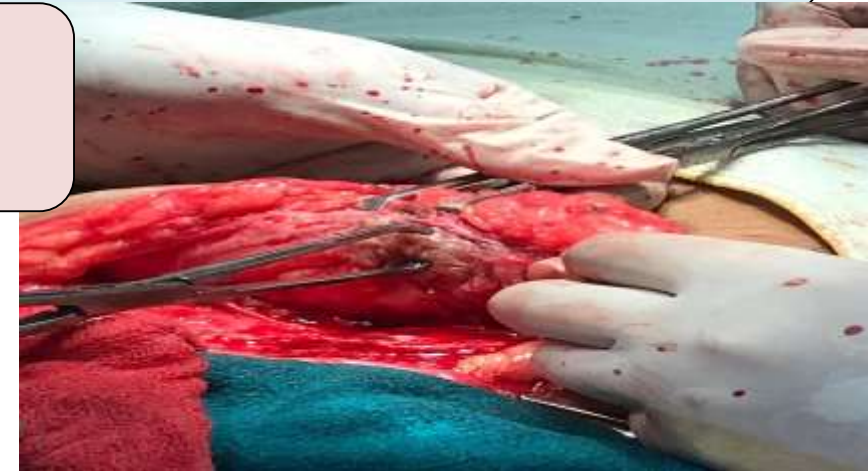
INTRODUCTION-Scar endometriosis is a rare form of endometriosis where endometrial-like tissue grows in or around surgical scars. It typically occurs after abdominal surgeries such as C-sections, hysterectomies, or laparotomies. While it is an uncommon complication, it can cause significant symptoms, including pain, swelling, and discomfort, often exacerbated during menstruation.g pain,

OBJECTIVES -To raise awareness of scar endometriosis as a clinical entity.

To evaluate the symptoms, diagnostic methods, and treatment options for scar endometriosis.

To highlight the importance of early recognition and intervention in improving patient outcomes.

CASE SUMMARY-A case report of 30 yr old healthy female with troublesome scar after caesarean section is presented. Surgical excision lead to diagnosis of scar endometriosis. Surgical history- uncomplicated caesarean section 6 years ago. She complained of increasing pain and tenderness at the incision site, Physical examination- a well healed caesarean scar with a non mobile, nodular, moderately pigmented area.



DISCUSSION-Scar endometriosis is a rare entity, presents in women who have undergone a previous abdominal or pelvic operation, Management includes both surgical excision and hormonal suppression. However, it is believed that hormonal is partially effective and surgical excision is the definitive treatment.

CONCLUSION- scar endometriosis presents diagnostic and therapeutic challenges due to its rarity and varied clinical presentation. A comprehensive understanding of its clinical features and management is needed.

REFERENCES-Diptee Poudel et al,A case of scar endometriosis in cesarean scar: A rare case report, International Journal of Surgery Case Reports 102 (2023) 107852